Routine Medical Care

Signs of Shock?

- ♦Pulse > 120
- ♦Pale, cool, diaphoretic skin signs
- ♦BP < 90/systolic
- ♦Altered mental status

If cardiac chest pain is suspected, and patient is able to swallow. Administer **Aspirin 162-325 mg PO** as soon as possible (tablet or chewable – not enteric coated)

NTG may be prioritized based on patient presentation

Perform 12-Lead EKG, as appropriate, and transport to cardiac receiving hospital if STEMI is identified (refer to 12-Lead EKG protocol). Alert STEMI center of possible STEMI, transmit 12-Lead EKG.

NOTE: if the patient has taken erectile dysfunction (ED) medication within the last 24 hours (Viagra/Levitra) or 36 hours (Cialis), withhold nitroglycerin. Aspirin should NOT be administered to patients with allergy to aspirin, or known sensitivity.

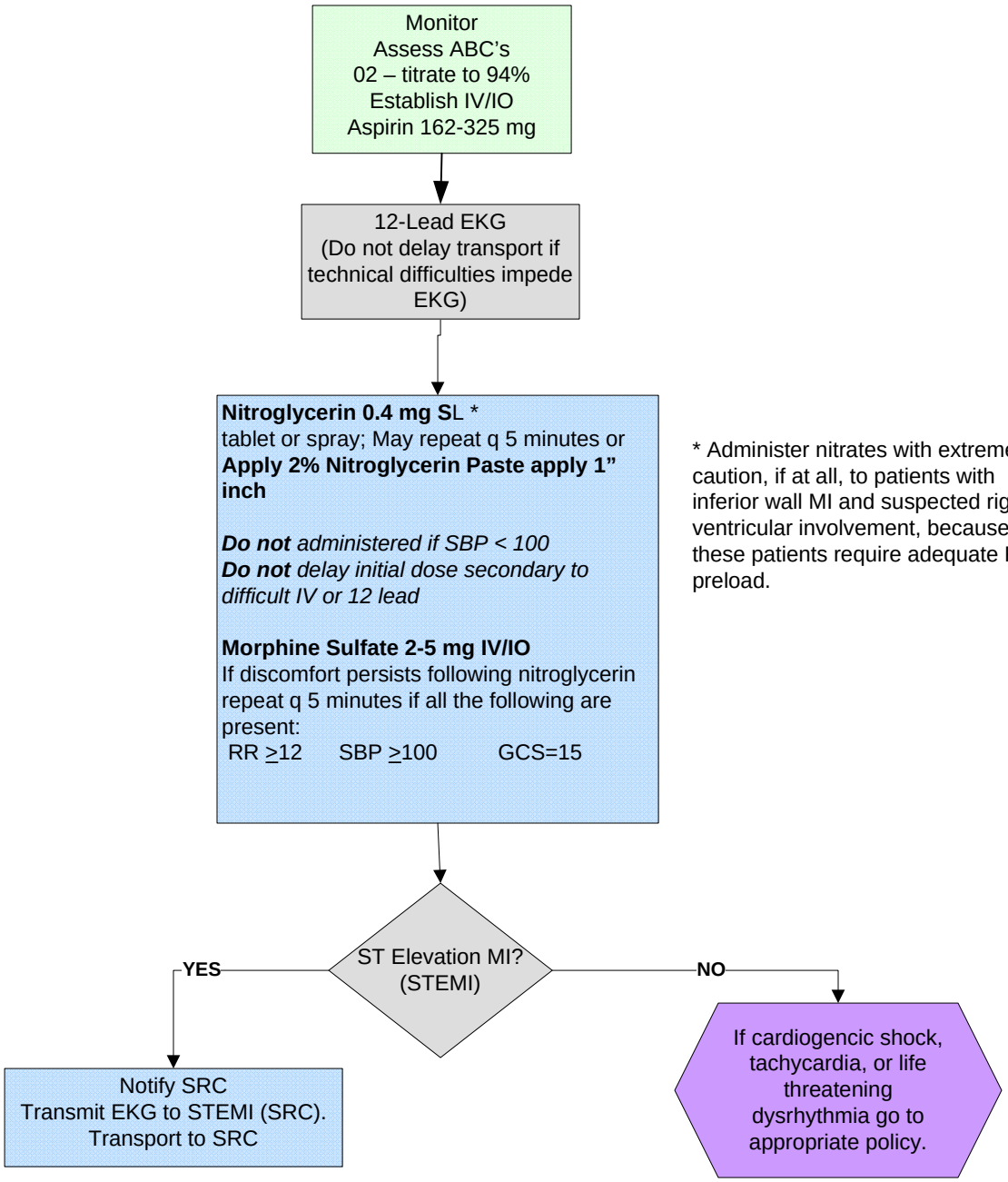

* Administer nitrates with extreme caution, if at all, to patients with inferior wall MI and suspected right ventricular involvement, because these patients require adequate RV preload.